

# A Psychological Profile of Children With Hemangiomas and Their Families

Edwin F. Williams III, MD; Marcelo Hochman, MD; Bret J. Rodgers, MD; David Brockbank, BA; Linda Shannon, MS; Samuel M. Lam, MD

**Objective:** To assess the psychosocial impact of hemangiomas and their treatment on children with the disease and their families.

**Design:** Thirty-nine children who were treated for hemangiomas were examined by a questionnaire that addressed the emotional attitudes of the parent and child toward the disease and the related treatment.

**Setting:** Two private ambulatory surgery centers (in Latham and Charleston).

**Results:** Overall, the survey found a negative effect on the child's family, with considerable fear caused in part by adverse public commentary or attitudes—which was ameliorated by education from the primary care provider and specialist. However, the family's perception was

that the child was not deeply affected by his or her condition and that treatment (laser, intralesional corticosteroids, oral corticosteroids, surgery, or a combination) did not change the child's emotional response to the disease. However, most parents observed that their child was too young to appreciate his or her malady.

**Conclusion:** Given earlier intervention for children with late-involuting hemangiomas and the advent of more effective therapies, our survey did not seem to indicate that the children experienced significant emotional trauma from their condition; nevertheless, their families experienced appreciable emotional and psychological distress.

*Arch Facial Plast Surg.* 2003;5:229-234

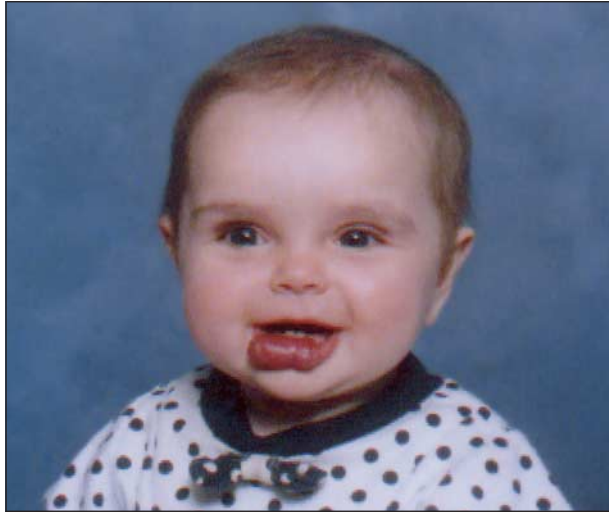From the Divisions of Otolaryngology (Drs Williams and Lam) and Facial Plastic & Reconstructive Surgery (Dr Williams), the Department of Surgery (Mr Brockbank), Albany Medical College, and the Vascular Birthmarks Foundation (Ms Shannon), Albany, NY; the Williams Center for Facial Plastic Surgery, Latham, NY (Dr Williams); The Facial Surgery Center, Charleston, SC (Dr Hochman); the Rodgers Center for Facial Plastic Surgery, Boise, Idaho (Dr Rodgers); and Lam Facial Plastic Surgery Center, Dallas, Tex (Dr Lam).

**H**EMANGIOMAS ARE the most common neoplasm of infancy and childhood, with an estimated prevalence of 1% to 3% of all neonates<sup>1,2</sup> and of 10% of infants by the age of 1 year.<sup>3,4</sup> Most hemangiomas arise in the head and neck region (60%), and 20% of patients may have more than one lesion.<sup>5</sup> Given these facts and that hemangiomas may be unsightly birthmarks (**Figures 1, 2, 3, and 4**), the psychological stress on the developing child and family cannot be underestimated. Hemangiomas exhibit a natural history of proliferation during the first year of life—a fact that may only further compound familial anxieties about the child's condition. However, only a few hemangiomas actually require intervention, because they often tend to involute before the age when the child should enter school. Most hemangiomas undergo involution during the second year of life, and may completely regress.

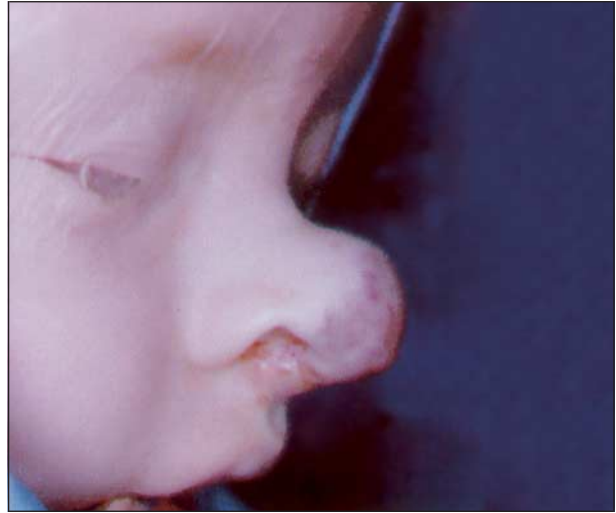If these often disfiguring vascular lesions do not involute early, they may have profound psychosocial effects on the child

and family, and may lead at times to accusations of child abuse and other misconceptions, as this study will show. In addition, reports of late-involuting hemangiomas have found a high incidence of a marked residual deformity. Although several studies<sup>6-12</sup> have investigated the impact that port-wine stains, or capillary vascular malformations, have on the child's psyche and the benefit that treatment affords, fewer studies<sup>13-15</sup> exist that examine the psychological ramifications of hemangiomas on the child and family.

Technological advances in the treatment of vascular lesions have also been remarkable and have kept stride with intellectual gains. Before the introduction of laser therapy, many individuals were left only with the option of cosmetic camouflage. The earlier laser types, the argon and Nd:YAG lasers, often led to undesirable scarring, an adverse effect rarely encountered with the pulsed dye laser. Some researchers<sup>16</sup> still advocate the efficacy of interstitial potassium-titanyl-phosphate and Nd:YAG lasers when treating the deeper component of the hemangioma not ame-



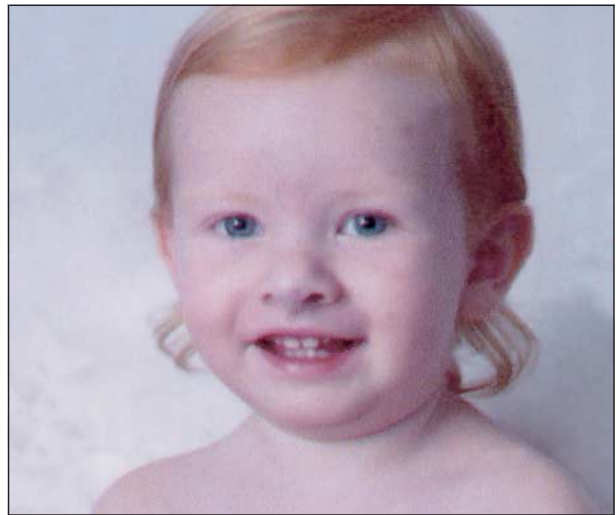**Figure 1.** A child with a rapidly expanding hemangioma of the lower lip at the age of 9 months, after oral corticosteroid therapy and immediately before 3 pulsed dye laser treatments.



**Figure 3.** A child with a nasal tip hemangioma before any treatments.



**Figure 2.** The child from Figure 1 at the age of 3 years, 1 year after surgery, which was performed because of the late-involuting nature of the lesion.



**Figure 4.** The child from Figure 3, after undergoing 3 pulsed dye laser treatments for a rapidly expanding hemangioma of the nasal tip and surgery to address the noninvolving nature of the lesion.

nable to the pulsed dye laser. Pharmacological intervention with corticosteroids (intralesional and systemic), interferon alfa-2a and -2b, and bleomycin sulfate has been investigated and implemented with varying success.<sup>17-19</sup> Surgery has remained a mainstay of therapy for those lesions that are refractory to the previously described methods or that are deemed more suitable to surgical debulking.

Given the recent advances in hemangioma management and the relative paucity of literature on the psychological sequelae of this disease, this article is intended to address these deficiencies and to provide a meaningful contribution to our understanding of the untoward psychological effects that hemangiomas may have on the child and family.

## METHODS

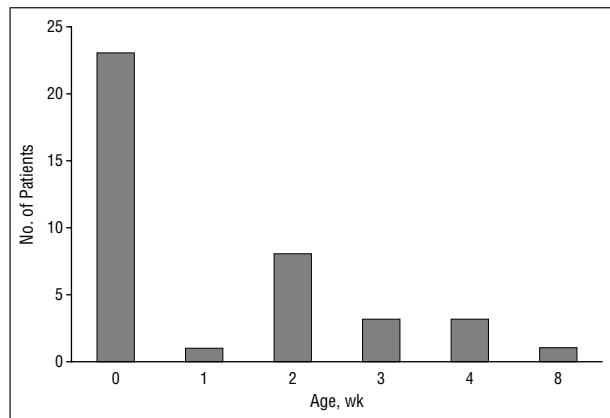
Thirty-nine families were interviewed by telephone about their child's hemangioma using a 38-point questionnaire that covered the child's birth history, the natural history of the heman-

gioma, physician encounters, treatment interventions, and the family's and child's emotional attitudes toward the hemangioma and related treatment. Initially, 112 medical records were evaluated for this study, but most were excluded from inclusion because of the presence of a vascular malformation rather than a true hemangioma, the lack of any therapy administered, or the inability to contact the family. Of the 39 patients, one of us (E.F.W.) treated 19 and another one of us (M.H.) treated the other 20. The female-male ratio was 29:10.

## RESULTS

### BIRTH HISTORY

The birth history of the child reveals a high incidence of complications (14 [36%] of 39), which included pre-eclampsia (n=4), prematurity (n=1), traumatic birth (n=2), hyperemesis (n=2), gestational diabetes mellitus (n=2), twin-twin transfusion (n=2), and failure to thrive (n=1). The one case of prematurity occurred at



**Figure 5.** Patient age at the onset of the hemangioma.

28 weeks' gestation. Slightly more than a third of the patients (13 [33%]) reported a family history of hemangiomas. Of the mothers, 14 (36%) took oral contraceptives before pregnancy, but all stopped their prophylactic medications 1 month before conception. None, however, took any fertility medications.

#### HISTORY OF THE HEMANGIOMA

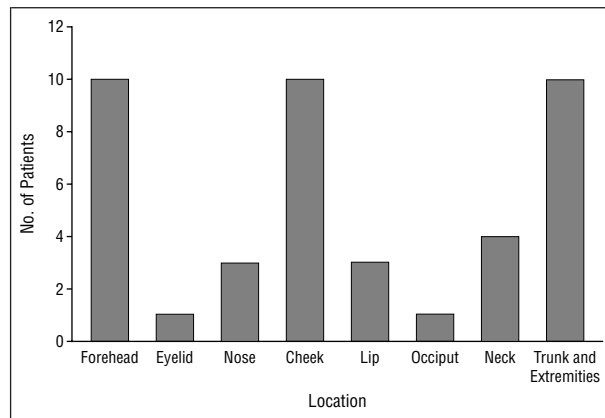
More than half (23 [59%]) of the hemangiomas presented at birth, and all were evident by the age of 2 months (**Figure 5**). Many treated hemangiomas occurred in the head and neck region (29 [74%]), most frequently on the cheek and forehead (**Figure 6**). Eleven children (28%) had multiple hemangiomas (range, 2-4 lesions; mean, 2.5 lesions). However, only 1 of the children had more than 1 hemangioma (specifically, 2 lesions) treated.

#### PHYSICIAN ENCOUNTERS

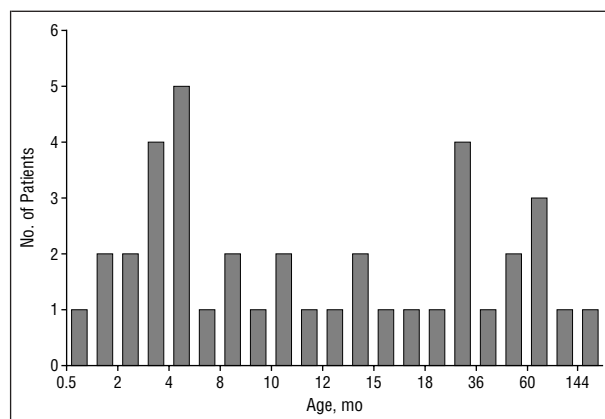
Parents attested to the accuracy with which their primary care physicians diagnosed the vascular lesion (37 [95%] of 39), and remarked that they recommended any treatment for only 9 (23%) of the lesions. (As stated, we selected all patients who eventually underwent treatment.) Nevertheless, these families sought more expert opinion from the Vascular Birthmarks Foundation at various stages in the evolution of the hemangioma, with the children ranging in age from 2 weeks to 12 years (**Figure 7**). All parents perceived that their visit to the Vascular Birthmarks Foundation was informative and that a treatment plan was clearly formulated. Of the parents, 38 (97%) professed that they could make a rational decision on the management of their child's hemangioma based on the information supplied by the Vascular Birthmarks Foundation.

#### TREATMENT HISTORY

As detailed in the introductory remarks of this article, the treatment algorithm was determined based on the guidelines enumerated by Williams et al.<sup>20</sup> Hemangiomas that were deemed rapidly proliferating in a cosmetically sensitive area (ie, the face and neck), that risked impending ulceration or had ulcerated, that were categorized



**Figure 6.** Location of the treated hemangiomas.



**Figure 7.** Patient age at presentation to the Vascular Birthmarks Clinic.

as late involuters, or that remained stable into the school years were candidates for therapy. Only patients who underwent therapy for their hemangioma were included in this study, to assess the psychological effects of the treatment intervention.

When treatment was recommended, the modalities used were pulsed dye laser, intralesional corticosteroid injections, oral corticosteroids, surgery, or a combination of the modalities mentioned. Of the patients, 31 (79%) underwent pulsed dye laser therapy (range, 1-10 treatments; mean, 3 treatments). Most patients (30 [77%]) were 1 year or younger, and underwent laser therapy to retard the proliferative nature of the hemangioma. Of the patients treated with the laser (7 of 31 or 23%), were significantly older ( $\geq 2$  years), and laser treatment was primarily aimed at eliminating dermal ectasias and/or reducing the residuum, and was often combined with surgery. Corticosteroids are only effective during the proliferative phase of the hemangioma, and treatment was confined only to this period. Intralesional corticosteroid injection was used in 7 patients (18%), with a range of 1 to 6 treatments (mean, 1.9 treatments). All corticosteroid injections were given as an adjunct to laser therapy during the proliferative phase of the hemangioma, because all patients were younger than 1 year. Oral corticosteroids were administered to 6 patients (15%) during the proliferative phase of the hemangioma, 4 of whom had therapy initiated before presentation at the Vascu-

**Table 1. Psychological Profile of 39 Patients With Hemangiomas and Their Families, Involving the Emotional Aspects of the Disease\***

Question	Strongly Agree	Agree	No Change	Disagree	Strongly Disagree
The presence of the lesion caused fears and anxieties in you and/or your family	17 (44)	17 (44)	0	4 (10)	1 (3)
The information you received from your primary care physician helped alleviate these fears and anxieties	6 (15)	17 (44)	3 (8)	8 (21)	5 (13)
The fears and/or anxieties decreased after you visited the Vascular Birthmarks Foundation	20 (51)	16 (41)	1 (3)	2 (5)	0
I encountered critical comments, negative stares, and/or opinions from others regarding my child's birthmark	26 (67)	9 (23)	1 (3)	2 (5)	1 (3)
This experience motivated me to find a specialty clinic	20 (51)	9 (23)	3 (8)	2 (5)	5 (13)
Fears and anxieties eliminated or decreased after your visit to the Vascular Birthmarks Foundation	17 (44)	20 (51)	1 (3)	1 (3)	0
The birthmark had a negative emotional effect on you and your family	7 (18)	14 (36)	3 (8)	11 (28)	4 (10)
The birthmark had a negative emotional effect on your child, who is affected by the birthmark	4 (10)	3 (8)	7 (18)	17 (44)	8 (21)
The birthmark adversely interfered with normal childhood activities, such as attending parties, playtime sessions, and day care	3 (8)	4 (10)	4 (10)	17 (44)	11 (28)
Were you ever accused of child abuse because of the birthmark?†	10 (26)	...	...	...	29 (74)

\*Data are given as number (percentage) of parents. Percentages may not total 100 because of rounding. Ellipses indicate data not applicable.

†Of the parents, 10 responded "yes" and 29 responded "no."

**Table 2. Psychological Profile of 39 Patients With Hemangiomas and Their Families After Treatment\***

Question	Strongly Agree	Agree	No Change	Disagree	Strongly Disagree
A change was noted in my child's self-esteem following treatment of the lesion	5 (13)	4 (10)	20 (51)	7 (18)	3 (8)
My child was less embarrassed	4 (10)	4 (10)	21 (54)	8 (21)	2 (5)
My child showed less avoidance of social gatherings	5 (13)	4 (10)	18 (46)	9 (23)	3 (8)
You had an improved relationship with the child	3 (8)	4 (10)	26 (67)	4 (10)	2 (5)
Overall, the emotional removal is as important as the physical removal of the birthmark	26 (67)	11 (28)	1 (3)	1 (3)	0

\*Data are given as number (percentage) of parents. Percentages may not total 100 because of rounding.

lar Birthmarks Foundation and 2 of whom began systemic therapy to treat an obstructing lesion (1 near the eye, and the other in the subglottic airway). Finally, surgery was performed, either once or twice, in 22 patients (56%) ranging in age from 2 months to 7 years.

### PSYCHOSOCIAL QUESTIONNAIRE

A 15-point questionnaire was then administered to assess the emotional and psychological effects that the hemangioma had on the family and the child (**Table 1** and **Table 2**). Parents were asked to respond to questions with one of the following opinions: strongly agree, agree, no change, disagree, or strongly disagree. The first part of the questionnaire pertained to the attitudes that the family and child had toward the hemangioma, and the second part concerned the emotional response to treatment. Parents expressed fear and anxiety toward the presence of the lesion. This anxiety was only partially alleviated by the primary care physician's advice regarding the hemangioma, but more parents professed that the advice delivered by the Vascular Birthmarks Foundation mitigated their concern.

Most parents testified to the negative commentary or stares they received from others, leading them to seek professional advice from a specialty clinic. Of the 39 parents, 10 professed that they were actually accused of child abuse because of their child's vascular lesion. Although

the hemangioma provoked anxiety in parents, a mixed response was given regarding the negative emotional effect on the family, and there was even less of an emotional burden on the child according to parents' perceptions. Similarly, the parents thought that the hemangioma did not adversely interfere with the child's social activities. However, parents acknowledged that their children were too young to appreciate their own condition.

The second half of the questionnaire addressed the emotional response of the parent and child to the treatment of the lesion (Table 2). Three questions that pertained to the child's attitude toward his or her condition after treatment received similar responses from parents, namely, that the child was not affected positively or negatively by the treatment (51% reported no change in self-esteem, 54% witnessed no change in the degree of embarrassment, and 46% claimed that no change occurred in the child's willingness to participate in social gatherings). Most respondents, however, qualified their opinions by declaring that their child was too immature to appreciate his or her condition. However, the few older children (n=8), who ranged in age from 3 to 8 years, revealed proportionally greater benefit from treatment compared with the younger children. Most parents of these older children thought that treatment effected significant improvement in the child's self-esteem (with 4 strongly agreeing, 2 agreeing, and 2 believing no change was evident). Also, they agreed that their children were

less embarrassed (with 3 strongly agreeing, 4 agreeing, and 1 believing no change existed). Overall, most parents (67%) confirmed that no change occurred in the relationship they maintained with their child after treatment. Nevertheless, 37 (95%) of the parents (26 [67%] who strongly agreed and 11 [28%] who agreed) believed that the emotional removal was commensurate to the physical removal of the hemangioma, which testifies to the intangible benefit that treatment may afford.

---

#### COMMENT

---

The treatment of vascular lesions has undergone a revolution in thought and practice in the past 10 years. Earlier intervention and advanced therapeutic modalities, such as laser therapy, have permitted the patient and family the opportunity to remove the hemangioma earlier and more effectively and, thereby, to mitigate the psychological impact that the hemangioma may otherwise have. The previously mentioned psychological profiles of patients with hemangioma and their family members were conducted, for the most part, before 1993, and may be considered outdated in some respects considering the new treatment algorithms and methods. In contrast, the psychological studies on port-wine stains were published principally at the turn of this millennium (1997-2000), and may reflect more current treatment designs.

The understanding of the nature and evolution of hemangiomas has been further refined since the seminal work of Mulliken and Glowacki,<sup>21</sup> who distinguished hemangiomas from vascular malformations based on the former's endothelial proliferative characteristics. Older terminology, such as capillary and cavernous hemangiomas and strawberry nevi, has been replaced with a more standardized nomenclature of superficial, deep, and compound hemangiomas. More recently, hemangiomas have been further subdivided clinically into early and late involuters, with the former resolving at the age of 1 to 2 years and the latter, after the age of 2 years. Based on these characteristics, an algorithm for early intervention has been proposed for the late involuters to avoid the attendant social stigma that would occur after entering school and further to address the substantial residuum often seen in these children.<sup>20</sup> Similarly, rapidly proliferative hemangiomas in a cosmetically sensitive area or those that risk ulceration are also treated early. The patients who were examined in this study were cared for following the guidelines of this new paradigm.

By virtue of their scientific nature, physicians are prone to measure the success of their treatment by objective criteria, such as removal of disease or avoidance of morbidity. At times, physicians look toward their patients for approbation and confirmation that their patients are satisfied with the care they have received. Rarely do physicians weigh the psychological burden that a disease process carries or, even less frequently, what steps should be taken to avoid the development of such emotional trauma. The psychological condition of the patient may be considered inaccessible or too elusive to ascertain reasonably in an objective fashion. Therefore, few studies have investigated the psychological importance

of a disease or how treatment may favorably alter the patient's outlook.

The management of hemangiomas has remained shrouded in uncertainty for many years, given the potential for these lesions to regress spontaneously. Many physicians have advocated a policy of benign neglect; the child is permitted to mature into early childhood without intervention. Newer studies have documented that many hemangiomas do not involute: one study<sup>22</sup> established that only 50% regressed by the age of 6 years, and of that group, 38% retained a marked cosmetic deformity. Based on these findings, hemangiomas that exhibit signs of late involution should be subjected to earlier management to avoid the potential psychological sequelae that this protracted waiting period may engender in the child.

The few psychosocial studies<sup>13-15</sup> that have examined the effects of late intervention have documented the real trauma that children and their families sustained from the presence of the hemangioma at such a late age. The child's body image is poorly developed before the age of 3 years, but by the age of 7 years, the child usually has a mature self-identity and is able to distinguish aesthetic concepts that may render the child feeling different from his or her peers. During the intervening years (the ages of 3-7 years), the child has already slowly acquired his or her perception of body identity, and it becomes imperative that the surgeon or physician intervene before this period to abort any negative social effects. The advantage of early intervention should be apparent for parent and child alike to avoid the negative social perceptions toward the parent and the ostracism that may ensue for the child at school.

This article underscores the importance of evaluating the psychological role that hemangiomas may have on the entire family unit and the fact that treatment should be tailored to curtail the damaging effects. Our findings overwhelmingly indicate that the parents believe the emotional burden matches the physical nature of the disease, and this opinion should help to guide physicians as they counsel their patients about treatment. However, a caveat must be offered at this point: parental anxiety should never dictate the timing of treatment because early-involuting hemangiomas have a high likelihood of complete regression and should be given the chance to do so. Premature intervention in stable, regressing, or nonobstructive lesions does a disservice to the child and the family. We must also consider the cost constraints dictated by insurance providers, yet maintain the need for treatment when appropriate. We believe that a judicious policy should be advocated—early intervention in hemangiomas that are rapidly proliferating or that fail to involute early to preclude the negative psychological impact on the developing child. In fact, the children in this study were not significantly affected by their disease process likely because they were too immature, an opinion that their parents repeatedly offered without provocation from the interviewer. The few older children who were enrolled in this study had proportionally greater psychological effects from their disease than their younger counterparts—a fact that supports our approach toward earlier intervention.

All children who were included in this study underwent therapy for their hemangioma—a fact that may predispose this study toward some bias. Only treated patients were studied to assess the disposition of the family and child toward the disease and to determine whether any beneficial change should arise from treatment. Clearly, younger and older children who never underwent treatment or who remained only under the care of their primary care physicians would be subjects worthy of further analysis. A multiarmed study in which treated and untreated children were examined in a prospective fashion would hold greater scientific merit. However, we believe that the proposed treatment algorithm represents a standard of care and that leaving patients intentionally untreated for the purposes of a scientific study would be inappropriate. Despite the limitations of this retrospective approach, we hope that this study should still encourage physicians to weigh the psychological dimensions with the more tangible physical attributes of the hemangioma when counseling the family and when deciding a course of therapy.

## CONCLUSIONS

The treatment of hemangiomas has undergone a remarkable transformation in the past decade, owing in part to a better understanding of the disease and a more effective therapeutic arsenal. Few studies have investigated the psychological ramifications of these particular vascular lesions on the child and family. Our results indicate that the parents bear the burden of psychological distress concerning their child's disease and that the young child remains relatively unaware of his or her condition, according to parents' perceptions. Earlier treatment protocols may account for the immature child's immunity from psychological repercussions. Further clinical studies are needed to confirm these preliminary findings.

Accepted for publication January 16, 2002.

This study was presented at the Eighth International Symposium of Facial Plastic Surgery, New York, NY, May 2, 2002.

Corresponding author: Edwin F. Williams III, MD, Williams Center for Facial Plastic Surgery, 1072 Troy Schenectady Rd, Latham, NY 12110.

## REFERENCES

1. Pratt AG. Birthmarks in infants. *Arch Dermatol*. 1967;67:302-305.
2. Jacobs AH, Walton RG. The incidence of birthmarks in the neonate. *Pediatrics*. 1976;58:218-222.
3. Holmdahl K. Cutaneous hemangiomas in premature and mature infants. *Acta Paediatr*. 1955;44:370.
4. Jacobs AH. Strawberry hemangiomas: the natural history of the untreated lesion. *Calif Med*. 1957;86:8.
5. Margileth AM, Museles M. Cutaneous hemangiomas in children: diagnosis and conservative management. *JAMA*. 1965;194:523-526.
6. Augustin M, Zschocke I, Wiek K, et al. Coping with illness and quality of life of patients with port-wine stains treated with laser therapy [in German]. *Hautarzt*. 1998;49:714-718.
7. Miller AC, Pit-Ten Cate IM, Watson HS, Geronemus RG. Stress and family satisfaction in parents of children with facial port-wine stains. *Pediatr Dermatol*. 1999; 16:190-197.
8. Strauss RP, Resnick SD. Pulsed dye laser therapy for port-wine stains in children: psychosocial and ethical issues. *J Pediatr*. 1993;122:505-510.
9. Augustin M, Zschocke I, Wiek K, Peschen M, Vanscheidt W. Psychosocial stress of patients with port wine stains and expectations of dye laser treatment. *Dermatology*. 1998;197:353-360.
10. Gupta G, Gilsland D. A prospective study of the impact of laser treatment on vascular lesions. *Br J Dermatol*. 2000;143:356-359.
11. Lanigan SW. Acquired port wine stains: clinical and psychological assessment and response to pulsed dye laser therapy. *Br J Dermatol*. 1997;137:86-90.
12. Troilius A, Wrangsjö B, Ljunggren B. Patients with port-wine stains and their psychosocial reactions after photothermolytic treatment. *Dermatol Surg*. 2000;26: 190-196.
13. Kunkel EJ, Zager RP, Hausman CL, Rabinowitz LG. An interdisciplinary group for parents of children with hemangiomas. *Psychosomatics*. 1994;35:524-532.
14. Dieterich-Miller CA, Safford PL. Psychosocial development of children with hemangiomas: home, school, health care collaboration. *Child Health Care*. 1992;21: 84-89.
15. Dieterich-Miller CA, Cohen BA, Liggett J. Behavioral adjustment and self-concept of young children with hemangiomas. *Pediatr Dermatol*. 1992;9:241-245.
16. Burstein FD, Simms C, Cohen SR, Williams JK, Paschal M. Intralesional laser therapy of extensive hemangiomas in 100 consecutive pediatric patients. *Ann Plast Surg*. 2000;44:188-194.
17. Bennett ML, Fleischer AB Jr, Chamlin SL, Frieden IJ. Oral corticosteroid use is effective for cutaneous hemangiomas: an evidence-based evaluation. *Arch Dermatol*. 2001;137:1208-1213.
18. Soumekh B, Adams GL, Shapiro RS. Treatment of head and neck hemangiomas with recombinant interferon alpha 2b. *Ann Otol Rhinol Laryngol*. 1996;105:201-206.
19. Sarihan H, Mocan H, Yildiz K, Abes M, Akyazici R. A new treatment with bleomycin for complicated cutaneous hemangioma in children. *Eur J Pediatr Surg*. 1997;7:158-162.
20. Williams EF 3rd, Stanislaw P, Dupree M, Mourtzikos K, Mihm M, Shannon L. Hemangiomas in infants and children: an algorithm for intervention. *Arch Facial Plast Surg*. 2000;2:103-111.
21. Mulliken JB, Glowacki J. Hemangiomas and vascular malformations in infants and children: a classification based on endothelial characteristics. *Plast Reconstr Surg*. 1982;69:412-422.
22. Finn MC, Glowacki J, Mulliken JB. Congenital vascular lesions: clinical application of a new classification. *J Pediatr Surg*. 1983;18:894-900.